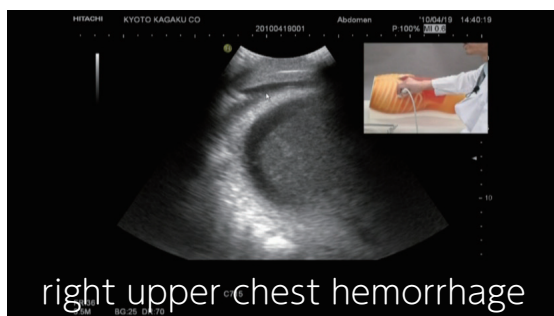
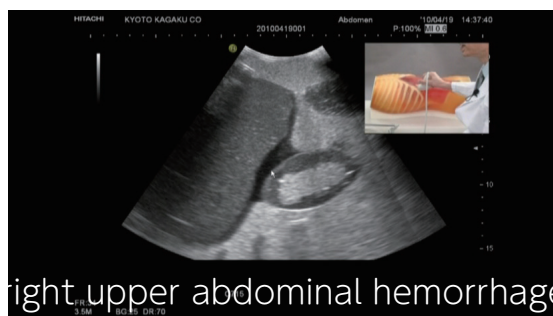


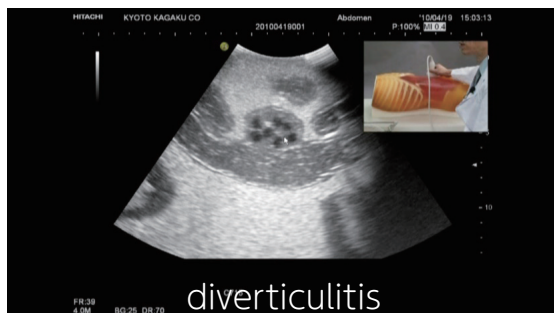
# US-5 Fast/Acute Abdomen Phantom "FAST/ER FAN"



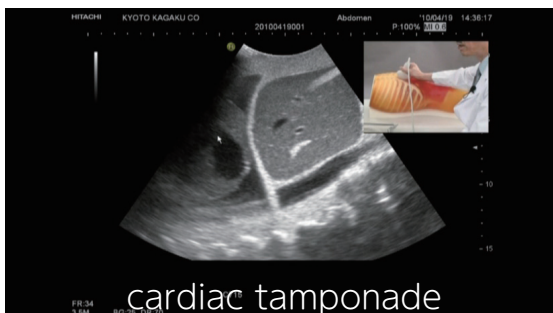
right upper chest hemorrhage



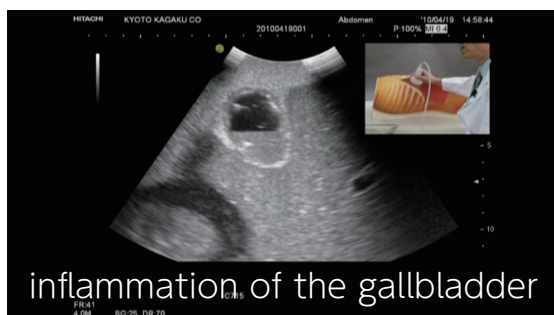
right upper abdominal hemorrhage



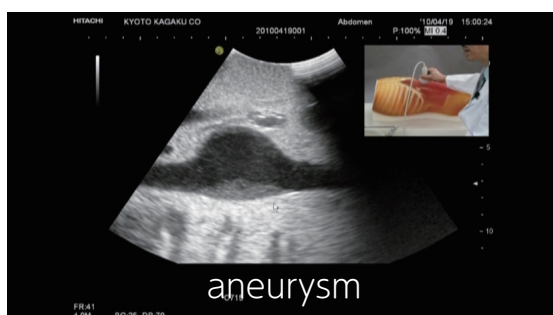
diverticulitis



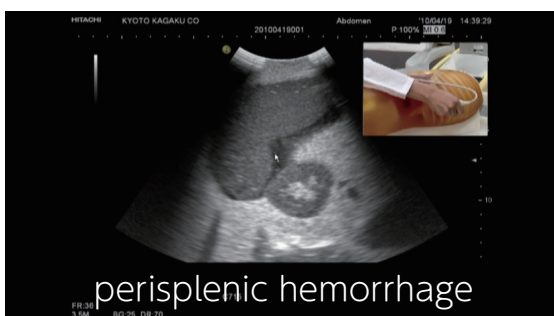cardiac tamponade



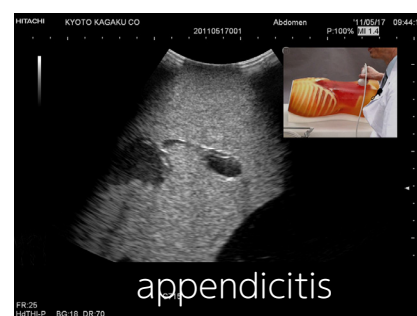
inflammation of the gallbladder



aneurysm



perisplenic hemorrhage



appendicitis