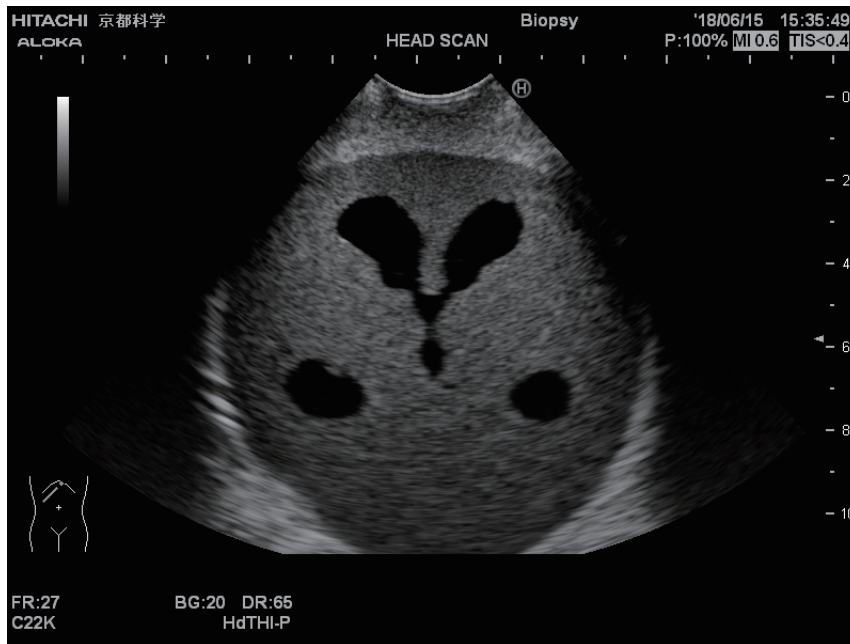
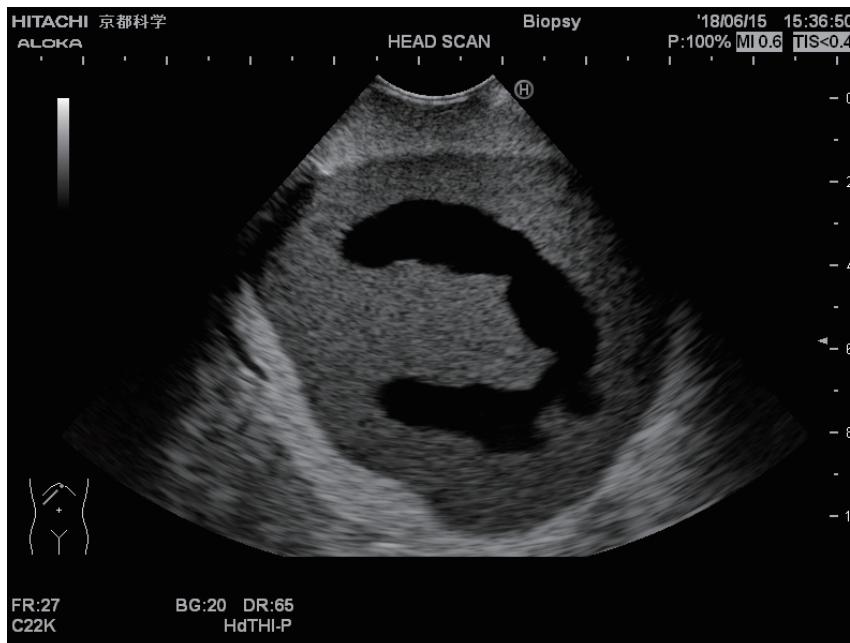


# US-14b Ultrasound Neonatal Head Phantom (Abnormal Type)



coronal plane



sagittal plane