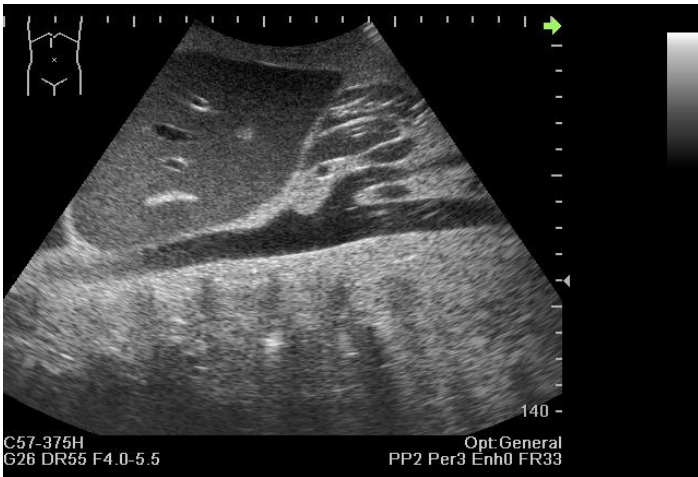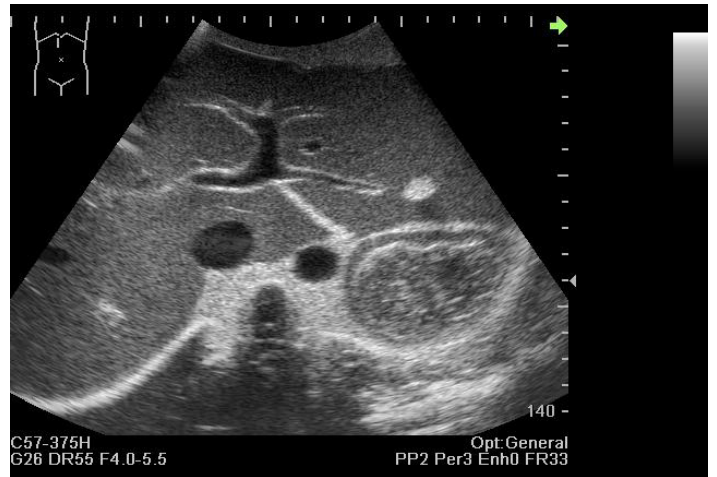


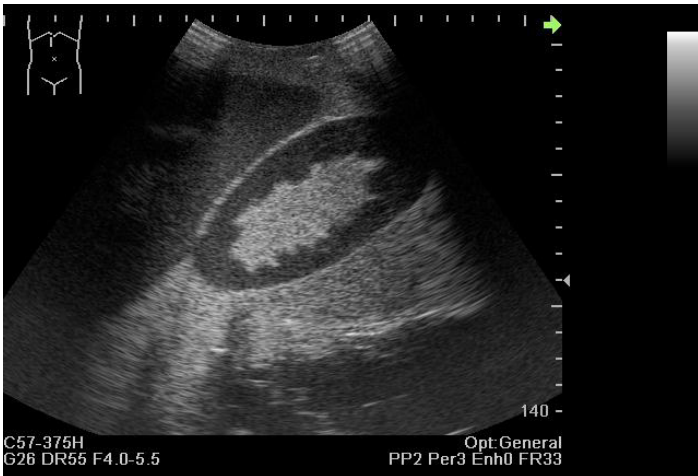
# US-1B Ultrasound Examination Training Model "ABDFAN"



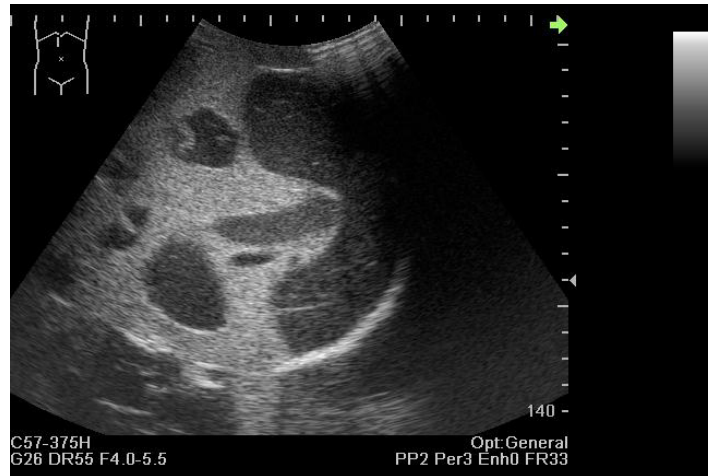
midsagittal plane



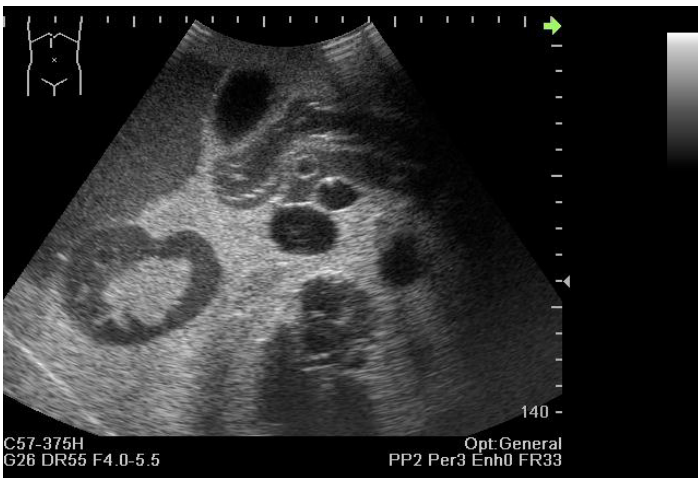
coronal plane, liver, portal vein



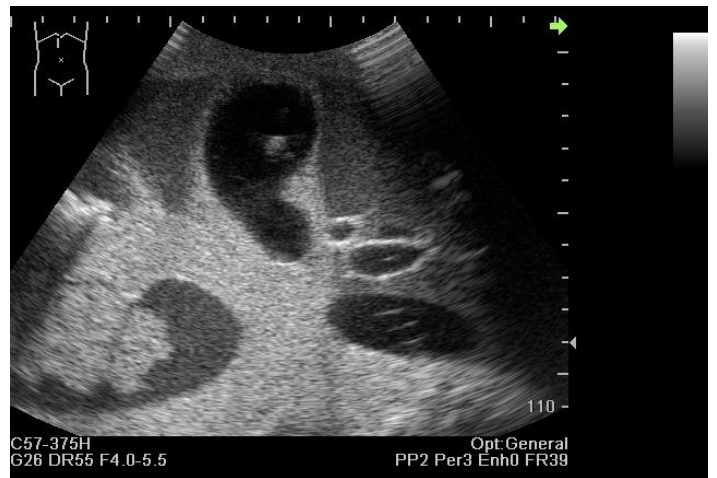
right kidney



spleen



gall bladder (transverse section)



gall stone